

MON 10 Heart in Mammals

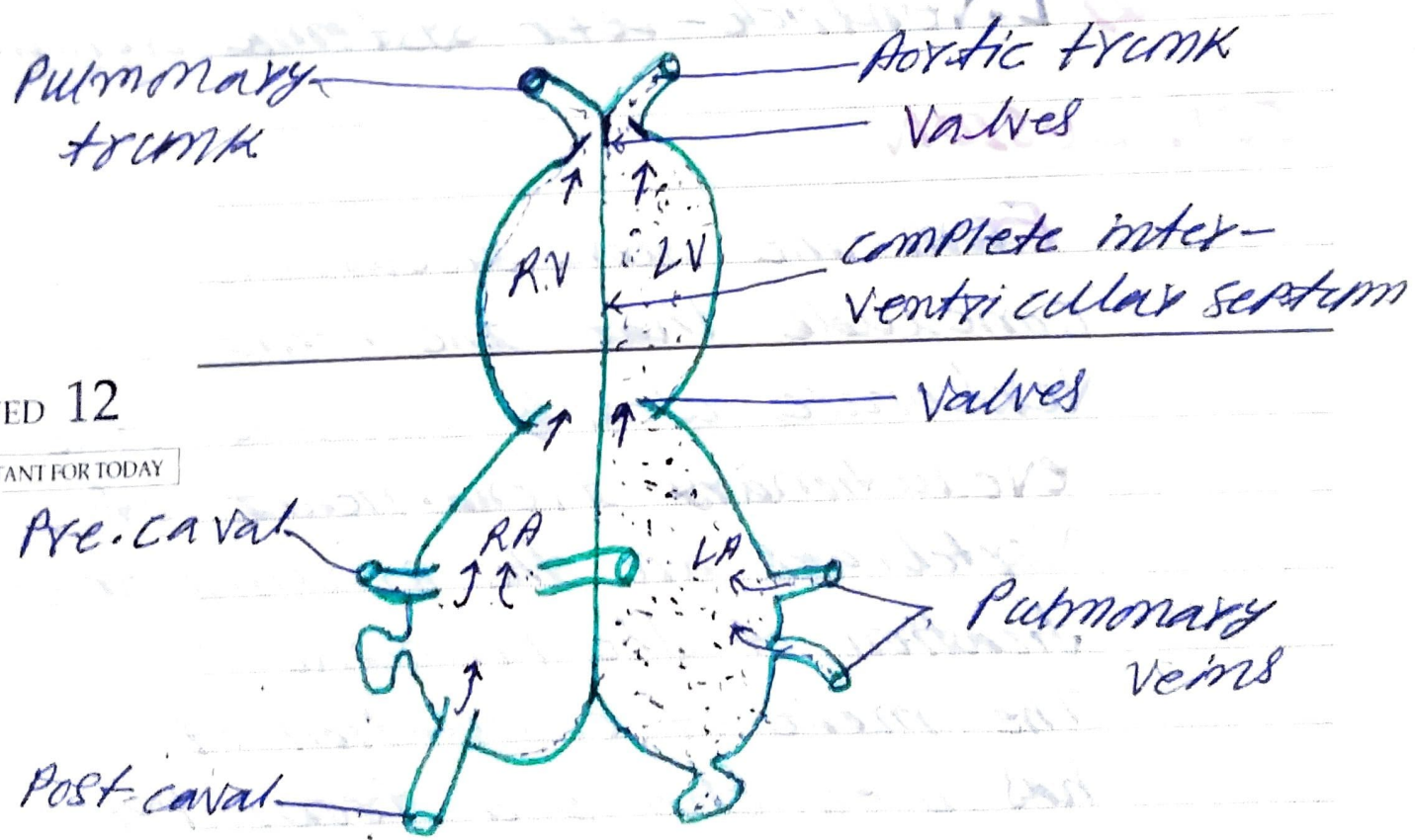
IMPORTANT FOR TODAY

- Completely 4 chambered heart are in birds (two auricles + two ventricles).
- The right-auriculo-ventricular aperture is provided with 3 tricuspid valves while the left auriculo-ventricular aperture is guarded by bicuspid or 1.

TUE 11

IMPORTANT FOR TODAY

- completely lacking of sinus-venosus. Therefore, three caval veins open directly into the right auricle.



WED 12

IMPORTANT FOR TODAY

Fig:- HEART IN BIRD & MAMMAL

2003  
MARCH

THU 13

IMPORTANT FOR TODAY

- The pulmonary veins open separately into the left auricles.
  - Conus arteriosus is disappeared.
  - The right ventricle leads into the pulmonary trunk (aorta) while the left ventricle leads into the left systemic aorta.
- 

FRI 14

IMPORTANT FOR TODAY

In mammals, the right systemic aorta is lost.

- 1) R. Ventricle - Pulmonary trunk
- 2) L. Ventricle - Left systemic aorta.

Pulmonary trunk

Aortic trunk

Valves

RV LV

complete inter-ventricular septum

Valves

WED 12

IMPORTANT FOR TODAY

Pre-caval

RA

LA

Pulmonary veins

Post-caval

Fig:- HEART IN BIRD & MAMMAL